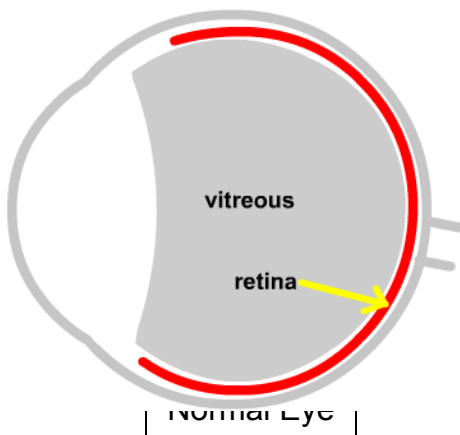




FLASHES & FLOATERS

One of the most common “normal” events that we evaluate in the office, particularly in the “over 50” age group, is the appearance of floaters. They are grey, brown, or red shadows that “float” within a portion of the peripheral (side) visual field of one eye, bobbing and swaying in response to eye and head movements. Like fingerprints, no two floaters are exactly alike, and the shape of any one floater may gradually change over months or years.

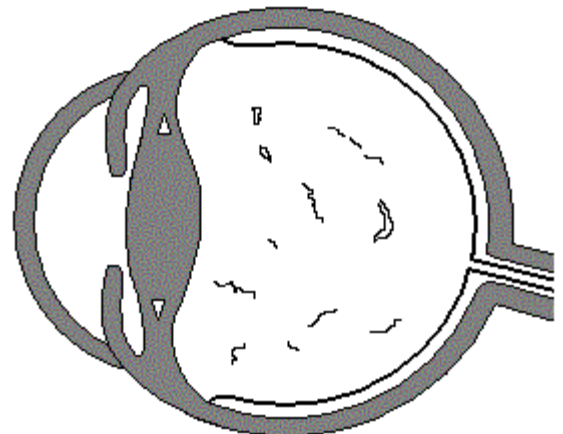
Most floaters develop as a result of natural changes in the vitreous, a clear, jellylike material that fills most of the eye. It is 98% water, and the remaining portion is primarily protein strands that give it a stiff consistency similar to gelatin. These vitreous strands have normal connections to the inner lining of the eye known as the retina.



The vitreous is important during the development of our eyes, but it doesn't seem to have much purpose afterward. During childhood, the vitreous completely fills its cavity like

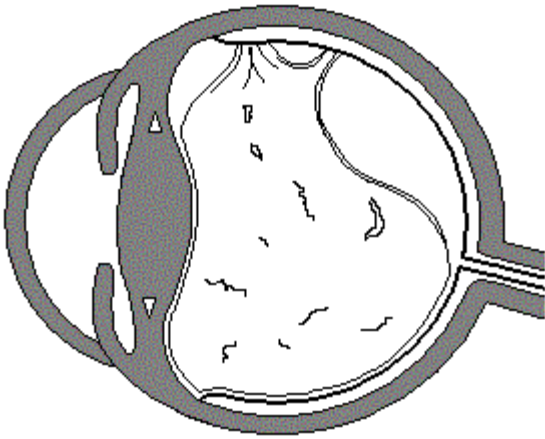
Jell-O fills a mold. Then, beginning in the early teens, it begins to “melt,” very slowly developing watery cavities. These cavities slowly enlarge, and eventually the entire vitreous shrinks and collapses.

As the fluid pockets lying next to the retina enlarge, the nearby vitreous-to-retina attachments stretch and break, eventually permitting the vitreous to float freely within its cavity. This is called “posterior vitreous detachment”. Usually this process occurs gradually,



but sometimes a more sudden event causes a abrupt onset of symptoms.

Floaters



Here is where the trouble may start. Each time a retinal attachment becomes stretched by a tug from the vitreous, the retina may be stimulated. Since the retina is a sensory nerve, and its sensory modality is “light,” we then see a flash of light. The light flash is usually faint and quick, similar to a

shooting star, and may be visible only at night. Quick head or eye movements may bring on more flashes, and the process can continue for months until all the attachments are broken.

Flashes

These flashers are not always just nighttime occurrences. Light flashes accompanied by new floaters, may be signs of a retinal tear. This may result from a very strong vitreous-retinal attachment refusing to break, pulling a hole in the retina itself. Such a hole is exceedingly dangerous, and can develop into a retinal detachment, which may require major eye surgery with uncertain prognosis. But, when found early, the holes usually can be easily repaired with lasers or freezing (cryotherapy). For this reason, all new flashes and floaters should be examined very carefully by an ophthalmologist. Early treatment prevents a retinal detachment.

Retinal tears and floaters are found more often in patients with high nearsightedness and previous injuries to the eye. Nearsighted eyes have a thinner retina, and an injury can result in premature vitreous “melting” or detachment. It is also interesting that the two eyes of an individual seem to behave similarly, with floaters appearing in the second eye within months of the onset of the first eye.

If left untreated, floaters becomes less bothersome because they move out of the central vision and farther away from the retina. Also, most people just seem to get used to them. “But, why can’t the doctor get rid of them?,” patients ask. Indeed, there are surgeries that remove the vitreous, but as with all high risk procedures, this is reserved for more serious reasons. Most sufferers are content to swat the nonexistent bugs now and then, and are comforted by the fact that virtually everyone goes through the process at some point in their life.

Always feel free to call our office if you have any sudden change in your floaters or flashers, or just have questions. We’re glad to hear from you!